

# Effect of Homeopathic *Arnica montana* on Bruising in Face-lifts

## Results of a Randomized, Double-blind, Placebo-Controlled Clinical Trial

Brook M. Seeley, MD; Andrew B. Denton, MD; Min S. Ahn, MD; Corey S. Maas, MD

**Objectives:** To design a model for performing reproducible, objective analyses of skin color changes and to apply this model to evaluate the efficacy of homeopathic *Arnica montana* as an antiechymotic agent when taken perioperatively.

**Methods:** Twenty-nine patients undergoing rhytidectomy at a tertiary care center were treated perioperatively with either homeopathic *A montana* or placebo in a double-blind fashion. Postoperative photographs were analyzed using a novel computer model for color changes, and subjective assessments of postoperative ecchymosis were obtained.

**Results:** No subjective differences were noted between the treatment group and the control group, either by the patients or by the professional staff. No objective differ-

ence in the degree of color change was found. Patients receiving homeopathic *A montana* were found to have a smaller area of ecchymosis on postoperative days 1, 5, 7, and 10. These differences were statistically significant ( $P < .05$ ) only on postoperative days 1 ( $P < .005$ ) and 7 ( $P < .001$ ).

**Conclusions:** This computer model provides an efficient, objective, and reproducible means with which to assess perioperative color changes, both in terms of area and degree. Patients taking perioperative homeopathic *A montana* exhibited less ecchymosis, and that difference was statistically significant ( $P < .05$ ) on 2 of the 4 postoperative data points evaluated.

*Arch Facial Plast Surg.* 2006;8:54-59

PHYSICIANS, PATIENTS, AND pharmaceutical companies are continuously trying to improve and expedite postoperative healing. Physicians modify techniques; patients try anecdotally successful home remedies; and pharmaceutical companies constantly test tissue glues and systemic agents in an attempt to find a combination that will result in a more rapid recovery. However, one of the most inconsistent aspects of this research, despite its obvious importance, has been the technique for evaluating outcomes. Given the inherently subjective nature of healing, most studies to date have evaluated postoperative outcomes using subjective scales. Many attempts have been made to quantify these subjective data and then to apply statistical analysis. The most accepted techniques have involved using visual analog scales (VASs) and ranking schemes. Patients and evaluators use linear VASs to indicate where a subject's symptom or sign falls along a spectrum from none to maximal; eg, the ecchymosis is rated as a "2 out of 10." Such attempts to quantify subjective outcomes are inherently flawed and subject to bias. Intricate ranking schemes, wherein evalua-

tors with expertise in the field rank photographs within a group as to their relative degrees of color changes, are somewhat more founded in their statistics, but still inherently subjective.<sup>1</sup> If the differences between individual subjects are subtle, these schemes become largely useless, as they cease to be reproducible.<sup>2,3</sup> As a result, researchers have turned to computers to help them perform more objective analyses. Magnetic resonance imaging has been used to assist in evaluating edema,<sup>4</sup> but no standard model exists for measuring color changes.

For a model to be accepted for widespread use, it must be readily available, user friendly, objective, and reproducible. While some computer models have improved the objectivity and reproducibility of such evaluations, their use has presented an onerous task to all but the most skilled computer users. Techniques such as laser Doppler, reflectance spectrometry, and tristimulus colorimetry have been used for this purpose, but their use has been limited owing to considerations about cost, ease of use, and the size of the area to be studied.<sup>3</sup> The desire to overcome these limitations prompted our selection of a widely available software pro-

**Author Affiliations:** Connecticut Facial Plastic Surgery, Farmington, Conn (Dr Seeley); Department of Facial Plastic Surgery, Vancouver General Hospital, Vancouver, British Columbia (Dr Denton); Aesthetic Wellness Center, Worcester, Mass (Dr Ahn); and The Maas Clinic, San Francisco, Calif (Dr Maas).

gram (Adobe Photoshop; Adobe Systems Incorporated, San Jose, Calif) that has arguably become the publication industry's standard for photographic analysis. Its wide range of features allows the user to use quick pull-down menus to perform complex pixel-by-pixel analyses of digital images. With this software, we were able to modify what we found to be the best model published to date.

In 1998, van der Horst et al<sup>5</sup> published their results using an objective analysis to evaluate color changes in port-wine stains after treatment with a flashlamp-pumped pulsed dye laser. They used a reflectance photometer that measured the color reflected off of the subjects' skin and quantified its composition with respect to the amount of red, green, and blue present. This method uses the  $L^*a^*b^*$  system, wherein a value between 0 and 100 is assigned to each parameter. Here,  $L^*$  denotes lightness (0 represents black and 100 white);  $a^*$  denotes the spectrum from green (0) to red (100); and  $b^*$  denotes the spectrum from blue (0) to yellow (100). We chose to use the same general approach, as van der Horst and colleagues' analysis was very logical and was found to have good reproducibility. However, we modified it to be more precise through the use of digital imaging, and we minimized variability using control regions within the photographs with an approach similar to that used by Rah et al.<sup>3</sup> We used our model not only to assess the degree of color change seen but also to measure the exact area affected.

As an initial application for this model, we sought to evaluate the efficacy of perioperative homeopathic *Arnica montana* as an antieccymotic agent. *Arnica montana*, also known as leopard's bane, is an herbaceous perennial of the family Asteraceae, which is indigenous to Central Europe and England. Referred to as a "miracle remedy," it has been used in varying formulations for centuries<sup>6</sup> to treat ailments as diverse as anxiety, motion sickness, and sciatica.<sup>7</sup> By far, its most common use today is in the setting of trauma, especially that of surgery. With innumerable potencies and purities available, we sought to evaluate the most readily available and widely used formulation. The homeopathic formulation retailed as SINECCH (Alpine Pharmaceuticals, San Rafael, Calif) is often endorsed by surgeons before elective surgery.<sup>8</sup> Therefore, there are 2 dilemmas: (1) there is controversy over whether *A montana* is effective, and (2) the debate over homeopathy persists, with almost religious advocates for both sides.

Homeopathy is "a system of therapy which focuses on health and wholeness rather than disease."<sup>9</sup> This science was founded by Samuel Hahnemann in Germany in the 18th century, after he consumed quinine (a remedy for malaria) and developed the symptoms of malaria. The cardinal rule of homeopathy, based on some of the teachings of Hippocrates, is the Law of Similars, or *similia similibus curentur* ("like is cured by like").<sup>9</sup> Simply stated, any substance that can cause symptoms when taken in a higher dose can also cure those very same symptoms in an unhealthy person when taken in a very small dose.<sup>10</sup> When *A montana* is ingested in large quantities, it can be toxic because it contains helenalin.<sup>11</sup> Its wide-reaching symptoms in high doses correspond with its reported numerous benefits, according to homeopaths. Numerous studies have yielded contradictory conclusions about its efficacy,<sup>12-17</sup> and many others have investi-

gated possible mechanisms.<sup>18-21</sup> One major meta-analysis of 89 placebo-controlled studies concluded that the effects reported could not be attributed solely to chance and thus advocated further investigation.<sup>22</sup> We present a prospective, randomized, double-blind, placebo-controlled study in which patients undergoing rhytidectomy were given either a placebo or SINECCH to take perioperatively, and both subjective and objective outcome measures were collected.

## METHODS

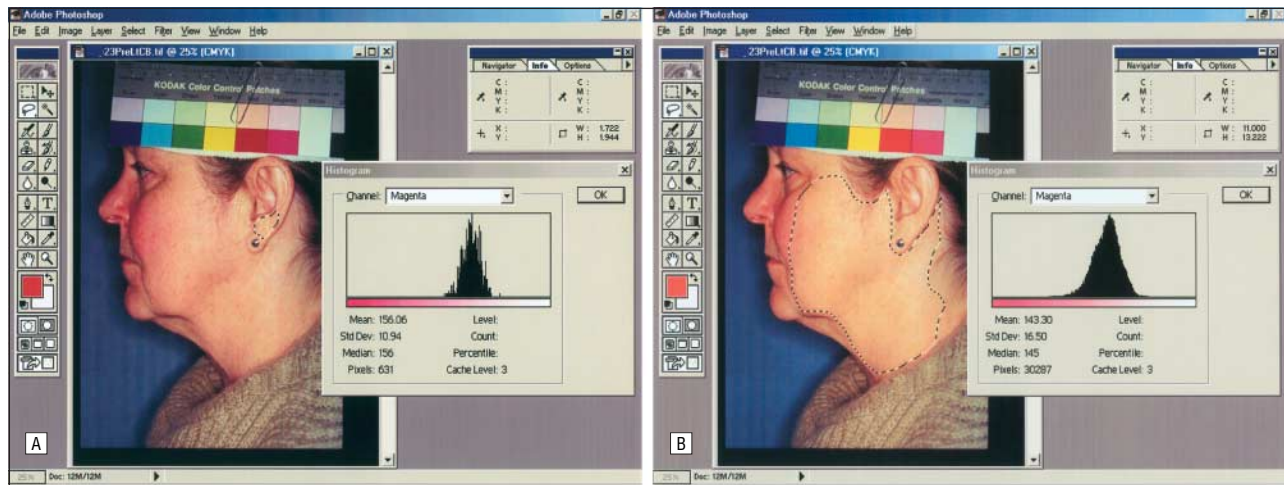
### PATIENTS

The Department of Biostatistics at the University of California, San Francisco, was consulted during the design and analysis phases of the study. The study protocol was also reviewed by the institutional review board, and all patients gave oral and written informed consents before undergoing surgery. Twenty-nine patients undergoing elective rhytidectomy were enrolled. All patients were white women who were nonsmokers. They also denied having tendencies toward easy bleeding and bruising, using recent aspirin or nonsteroidal anti-inflammatory drugs, and having undergone any previous facial surgical procedures. They were not interested in any ancillary procedures, and they completed the standard medical, physical, and psychological evaluations, which are performed in all of our rhytidectomy cases.

At the preoperative office visit, standard medical photography was performed. For the purposes of the study, bilateral profile images were obtained using standardized illumination with the same camera, focal length, aperture, film type, and processing technique. Included within the study field (but not obscuring the planned operative field) were color-control bars (Eastman Kodak, Rochester, NY) with a reference ruler. Patients were assigned study numbers and randomly given a regimen of either placebo or SINECCH in a double-blind fashion. On the morning of surgery, the patients took the first of their 12 doses, with the remainder being taken every 8 hours for a total of 4 days. Patients underwent cervical liposuction and a geometric SMAS (superficial musculoaponeurotic system)-plasty rhytidectomy, a multivector/multiplanar procedure advocated by the senior author (C.S.M.). No ancillary procedures were performed; bilateral suction drains were used; and all patients were bandaged with a Barton dressing. No tissue glues were used.

On the first postoperative day (POD 1), the drains and dressings were removed; the patients were photographed in the standardized fashion; and a VAS was completed by the registered nurse or the physician in the office. The scales were the same as those completed daily by the patients over the first 2 postoperative weeks. For each day, a mark was made along a 10-cm line representing the degree of perceived ecchymosis. Headers across the top ranged from none to severe, and a reference picture (moderately severe) was used (marked at the 8-cm point). For the purpose of calculations, each mark was ultimately converted into a number from 0 to 100, corresponding to its position, in millimeters, along the line. The VAS and the photographs were repeated by the physician or the nurse on PODs 5, 7, and 10. Finally, patients were asked to note the date when they felt comfortable going out to eat in a restaurant.

With all of the data collected, the photographs were then analyzed. Each 35-mm slide was converted into a digital (tagged image file format [TIFF]) file using a digital camera (COOLPIX995; Nikon Corporation, Tokyo, Japan) and a slide-copying adapter (ES-E28; Nikon Corporation). For this process, high-resolution settings were used: "full" (2048 × 1536



**Figure 1.** Screen image of a patient before surgery ( $X=20.30$ ). A, Earlobe control, magenta channel. B, Anticipated area of ecchymosis.

pixels), “fine” (uncompressed), and ISO 100. After the image was saved as a digital file, it was opened with the image editing software (Adobe Photoshop 5.5). The file was “zoomed” to fit entirely on the screen (to 25% of its original size) and converted into the CMYK mode (under the “image” pull-down menu, “mode” and “CMYK” were selected).

The CMYK color mode differs from the previously described laboratory mode in that its 4 components are cyan, yellow, magenta, and black. The 3 former colors are the primaries for subtractive light; eg, when cyan ink is used, all other colors are absorbed, and only cyan is reflected and thus perceived by the eye. These primary colors are in contrast to the additive primary colors of red, green, and blue. When red, green, and blue lights are added, the result is white light (all wavelengths of visible light together). When cyan, yellow, and magenta inks are combined, the result is black, or close to it (all wavelengths are absorbed). Since true black is hard to achieve, most printing processes add black ink (abbreviated as K, so as not to confuse it with blue).<sup>23</sup>

The CMYK color mode (as opposed to laboratory or red-green-blue mode) was selected for 2 major reasons. First, ours is an analysis of a 35-mm slide, which was created with a processor that uses cyan, magenta, yellow, and black inks. Second, after the color composition of a number of ecchymoses was analyzed, it became apparent that each of these components increases with bruising; the so-called black and blue components are obvious, but the presence of increased blood and its breakdown products yields an increase in magenta and yellow as well. Since our ultimate goal was to measure the change in a composite color based on changes in its components, it made sense to use a mode in which each of the components changed, not one in which 2 color changes (eg, an increase in blue and yellow in the laboratory mode) might offset one another and yield no numerical difference.

After the image was converted into the CYMK mode, the control area was outlined using a commercially available pen tablet (Graphire2; Wacom Company, Ltd, Vancouver, Wash). We believe that the stylus allows more precise outlining than a mouse does. The use of a control area within the image was crucial to our model. This control area was a part of the same image as the area being analyzed and was therefore subject to exactly the same illumination and filming conditions. The control area (the earlobe [preferred], the temple skin, or the skin of the posterior cervical triangle) was chosen based on its meeting 4 criteria. First, it had to be plainly visible, unobscured by hair or the color-control patch, in each of the photographs for a given subject. Second, it had to be far enough out of the field of surgery so as not to be subject to ecchymotic changes after

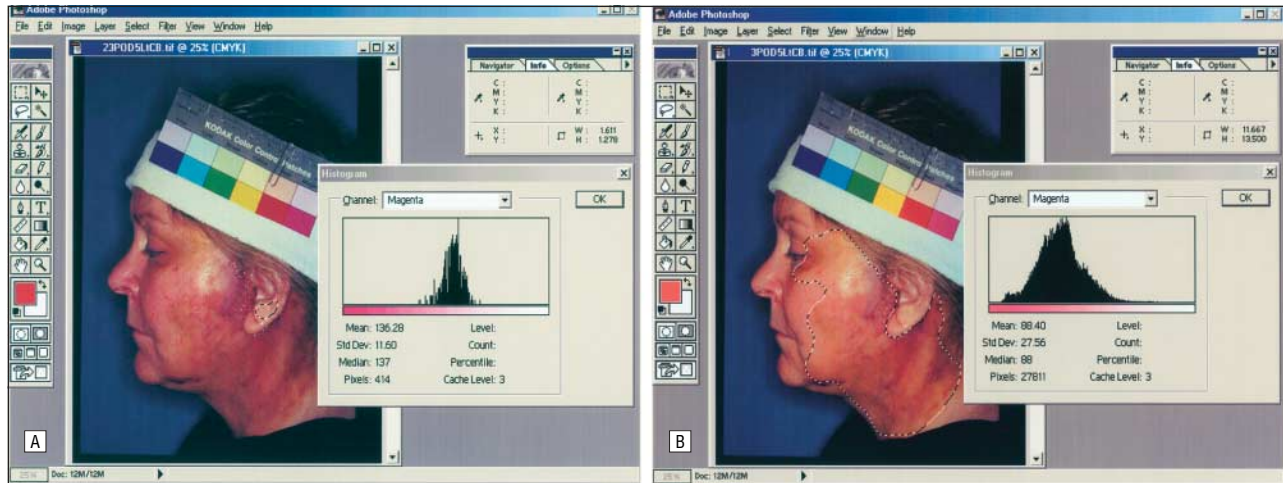
surgery. Third, it had to be in approximately the same plane as the anticipated area of ecchymosis (and thus in focus). Fourth, it had to be paler than the study area. The goal in this analysis was to obtain a numerical value for the *difference* between the mean color of the study area and that of the control area. These calculations were made both before and after surgery. If, for example, the control area were found to be darker than the study area (cheek) before surgery, then a darkening of the cheek, such as with ecchymosis, might actually be perceived as a decrease in color difference.

After the control area was outlined, its color composition was determined using the “histogram” feature under the image pull-down menu (**Figure 1A**). (By accessing the histogram, information can be obtained about each of the component color channels. The histogram indicates exactly how many pixels are present within the outlined area and lets the user know the mean value, on a scale from 0 to 255, for each color.) Then, the mean value for each of the 4 CYMK channels was noted, as was the mean value for luminosity, which is a measure of the degree of lightness of the composite color. In each case, the value of 255 represented pure white, and the value of 0 represented the pure color, or absolute absence of light in the case of luminosity.

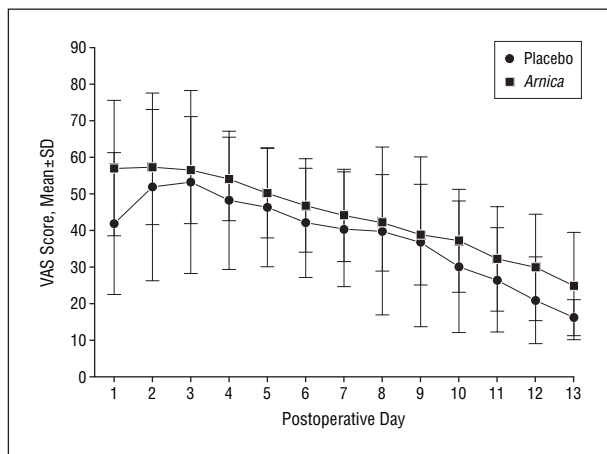
After the data for the control area were collected, the complete process was repeated after the study area was outlined, thus yielding the numbers for comparison (**Figure 1B**). These numbers were then entered into the formula for color difference ( $X$ ), where  $X = (\Delta C^2 + \Delta Y^2 + \Delta M^2 + \Delta K^2 + \Delta L^2)^{1/2}$ . Here,  $\Delta C$  represents the difference between the mean cyan value for the study region and that of the control region, and so on. The number represented by  $X$  is unitless; it is merely a numerical value that represents the degree to which 2 colors differ. Accordingly, if 2 colors were compared and found to have an  $X$  of 4.3, they might be nearly indistinguishable to the naked eye. A value of 20.30 might be seen as a mild difference, such as “rosy cheeks” (**Figure 1**). If, however, their  $X$  value were 114.76, they would be dramatically contrasting colors (**Figure 2**). For each image, then, an  $X$  value was obtained, indicating the difference between the mean color of the surgical field and that of the control area. When the preoperative  $X$  value was subtracted from a given postoperative value, the net difference represented the color change attributable to surgery (ie, the degree of ecchymosis).

The last piece of data collected was the area of ecchymosis. After a square of known area on the color bar within a given image was traced out, and the histogram feature on that area was used to reveal its pixel content, the exact density of pixels per square centimeter for that image was calculated. This density was then extrapolated to the study area, which had a known

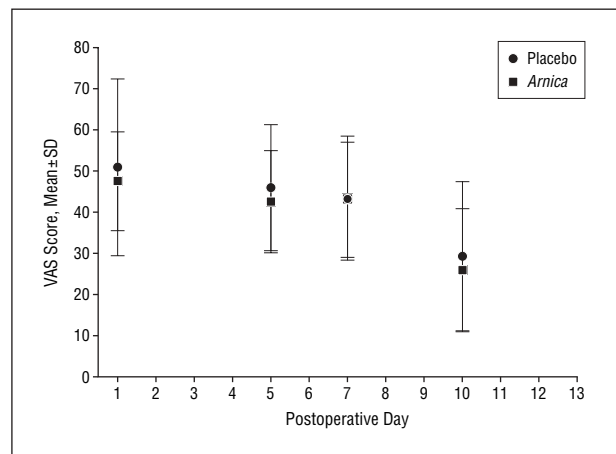




**Figure 2.** Same patient as in Figure 1, with (exceptionally high) score of 114.76 (net change, 94.46) on postoperative day 5. A, Minimal change in earlobe (owing to lighting subtleties). B, Extensive ecchymosis, marked magenta component.



**Figure 3.** Subjective visual analog scale (VAS) scores, reported by patients. Note extensive variability. No difference noted.



**Figure 4.** Subjective visual analog scale (VAS) scores, reported by registered nurse or physician. Note extensive variability again. No difference noted.

number of pixels, and thus an exact area of ecchymosis was calculated, despite its markedly irregular borders.

## RESULTS

### SUBJECTIVE EVALUATION

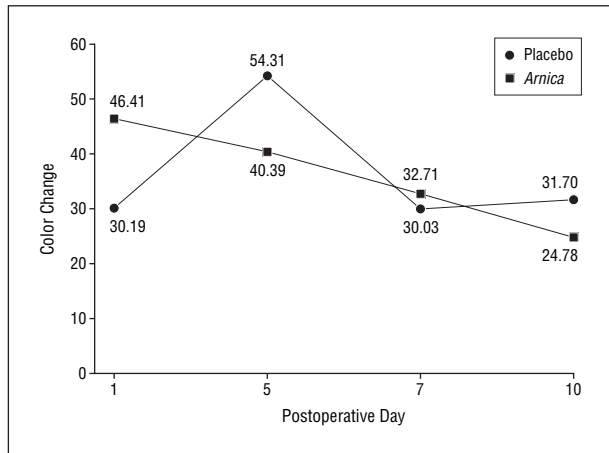
Of the 29 patients enrolled in the study, 26 (90%) completed the VAS (**Figure 3**). Twelve (46%) of the 26 patients were in the control group, while 14 (54%) received *A montana*. Patients in both groups followed a trend of steady recovery starting at POD 3, resulting in resolution of all but a minimal amount of ecchymosis within 2 weeks. While the patients in the *A montana* group actually did worse than those in the control group at each time point, these data were not found to be statistically significant ( $P > .05$ ,  $t$  test) on any day, as the differences were minimal and the variability was high. There were no complications in either group.

All 29 patients were subjectively evaluated by a registered nurse or a physician on a separate VAS (**Figure 4**). Fourteen (48%) of the 29 patients received *A montana*, while 15 (52%) received the placebo. Data for this VAS were ob-

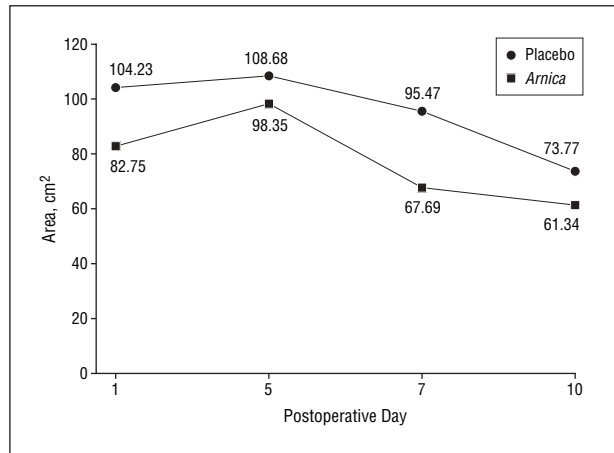
tained only on PODs 1, 5, 7, and 10; a general trend in resolution of ecchymosis was seen throughout this period. In contrast to the data obtained from the patients, the *A montana* group did better than the control group at all time points, but again these differences were minimal and the variability was high; therefore, no statistically significant difference ( $P > .05$  at all data points) was noted. Finally, when asked to note the day when they felt comfortable going out to dinner, the patients in the control group reported a mean  $\pm$  SD of  $10.6 \pm 3.9$  days, while those in the *A montana* group reported a mean  $\pm$  SD of  $11.2 \pm 3.8$  days. The difference was not statistically significant ( $P = .8$ ,  $t$  test).

### OBJECTIVE EVALUATION

Given the enrollment of 29 patients, each of whom had 2 profile images taken at each of 5 time points (before surgery and on PODs 1, 5, 7, and 10), a complete data set would have included 290 images. We ultimately used 253 images (87.2%), as 37 (12.8%) were either of insufficient quality for analysis or unavailable owing to patient noncompliance with follow-up. The X value, or degree of color change attributable to surgery, was charted



**Figure 5.** Postoperative color changes (calculated as  $X_{\text{postoperative}} - X_{\text{preoperative}}$ ). No difference was statistically significant.



**Figure 6.** Area of ecchymosis. Differences statistically significant at postoperative days 1 ( $P=.005$ ) and 7 ( $P<.001$ ).

**Table 1. Sample Sizes and Color Change Data for Placebo (P) and *Arnica montana* (A) Groups\***

	No. (P)	No. (A)	Color Change vs Preop (P)	Color Change vs Preop (A)	P Value
Preop	30	28			
POD 1	25	20	30.19	46.41	.09
POD 5	22	23	54.31	40.39	.16
POD 7	30	21	30.03	32.71	.79
POD 10	28	26	31.70	24.78	.47
<b>Total</b>	<b>135</b>	<b>118</b>			

Abbreviations: Preop, preoperative; POD, postoperative day.  
\*The total for both groups is 253.

**Table 2. Area Data for Placebo (P) and *Arnica montana* (A) Groups\***

	No. (P)	No. (A)	Area, cm² (P)	Area, cm² (A)	Difference, No. (%)	P Value (Area)
Preop	30	28				
POD 1	25	20	104.23	82.75	21.48 (20.60)	.005*
POD 5	22	23	108.68	98.35	10.33 (9.50)	.19
POD 7	30	21	95.47	67.69	27.78 (29.10)	<.001*
POD 10	28	26	73.77	61.34	12.43 (16.85)	.13
<b>Total</b>	<b>135</b>	<b>118</b>				

Abbreviations: Preop, preoperative; POD, postoperative day.  
\*Difference expressed as percentage of decrease compared with placebo group.

for comparison (**Figure 5**). Patients in the placebo group started out on POD 1 with a mean score of 30.19, which then rose to 54.31 on POD 5 and plateaued at 30.03 and 31.70 on PODs 7 and 10. Patients in the *A montana* group showed more discoloration on POD 1, with a mean score of 46.41, and then showed steady improvement, with subsequent scores of 40.39, 32.71, and 24.78. Using the *t* test, these differences were not statistically significant ( $P>.05$ ) at any time point (**Table 1**).

With respect to area, patients in the *A montana* group showed less ecchymosis at all time points (**Figure 6**), with these data being statistically significant ( $P<.05$ , *t* test) only on PODs 1 and 7. On a percentage basis, the patients in the *A montana* group were found to have between 9.50% and 29.10% less ecchymosis than those in the placebo group (**Table 2**).

## COMMENT

The model described herein represents a significant advancement in the objectification of skin color changes. It builds on previously validated models in several ways. First, the inclusion of a control region within the study image eliminates all other photographic and processing variables. With standardized photography, these variables are minimized, but with such precise analysis, even the slight-

est differences can be seen; therefore, improved controls are needed. Second, the model is simple to use. While the analysis itself is rather complex, the investigator only needs to circle the study areas and perform a series of mouse clicks to complete the analysis; the rest is done by widely available software. Third, the increase in the number of channels used (5 in CMYK mode vs 3 in laboratory mode), and the increase in the number of colors along each gradient provided by 24-bit graphics (256 vs 100) results in a much more precise evaluation and is able to detect much more subtle color changes (16.78 million colors). Finally, the addition of the area component of the analysis allows the investigator to add another outcome measure, despite irregular borders that inhibit traditional area analyses.

In future studies, we recommend 2 major modifications. When this study was undertaken, 35-mm slides were the standard in the senior author's practice. With high-quality digital photography now readily available, we will complete future studies using this modality, thus eliminating the conversion step. Furthermore, we will likely forgo the use of a color bar and include a square sample of known dimensions and color composition as a control. Using a pale flesh-toned control card (placed above and behind the ear, obscuring only hair) will expedite the analysis and further eliminate variables. As a point of technique, we would emphasize the need for strict adherence to standardized photography. Several images in this study were unusable either

because of glare (reflection of light off of skin with residual antimicrobial ointment on it) or because of inattention to detail (such as allowing the patient's hair to obscure some of the study area). With digital photography, images will be instantaneously evaluated and can thus be repeated if necessary. These additions should improve the quality and significantly facilitate further studies.

For our initial investigation using this model, we evaluated homeopathic *A montana*. No subjective differences were noted by either the patients or the evaluators, and perhaps the most telling aspect of these data are their wide variability (Figure 5), which underscores the need for objective evaluation. Nonetheless, one could certainly argue that, despite all of the intricacy and science behind the model, the most telling statistic is the lack of effect of *A montana* on expediting patients' recovery to the point that they feel comfortable enough to go out in public.

With respect to objective color changes, the trend is of interest. While no significant differences existed at any point, the patients in the *A montana* group showed greater ecchymosis on POD 1, and then got progressively better. The patients in the placebo group got worse by day 5, and then better. While measuring edema was beyond the scope of this study, it is at least theoretically possible that *A montana* could account for a decrease in edema immediately after surgery, which may coincide with more obvious (less hidden) ecchymosis, followed by recovery—a phenomenon that might occur relatively later in the placebo group. A formal study would be needed to evaluate the role of edema, and larger sample sizes would be helpful.

The data regarding the area of ecchymosis are somewhat inconsistent. At each data point, the *A montana* group had less bruising, and the difference was extremely significant on PODs 1 and 7. That the 2 groups trended toward complete resolution by POD 10 would explain the lack of difference there, but the effect seen on POD 5 remains unexplained. With further advances in computer models, including the improvement of 3-dimensional photography, the complex interplay of tissue swelling and color changes may be more readily analyzable.

## CONCLUSIONS

We have developed an objective computer model that is a useful tool for the analysis of skin color changes. This model is widely available, easy to use, and provides the investigator with precise, reproducible, and objective data. Thus far, our application of this model has been limited to the analysis of the degree and area of postoperative ecchymosis. While future improvements will certainly be made, in its current state it provides a much needed tool for objectively evaluating color changes. As such, its potential applications for evaluating surgical outcomes are numerous, and its use in future studies will provide much needed objectivity.

In our prospective study, we found no subjective differences between patients undergoing elective rhytidectomy who were given perioperative homeopathic *A montana* and those who were given a placebo. Objectively, we found no significant difference in the degree of ecchymosis, as measured by the extent of color change found. Pa-

tients in the *A montana* group did, however, have a smaller area of ecchymosis than those in the placebo group. This difference was found to be statistically significant on POD 1 and 7 ( $P < .05$ ) but not on POD 5 and 10.

**Accepted for Publication:** September 22, 2005.

**Correspondence:** Corey S. Maas, MD, The Maas Clinic, 2400 Clay St, San Francisco, CA 94115 (drmaas@drmaas.com).

**Funding/Support:** This study was supported in part by a research grant from Alpine Pharmaceuticals, makers of SINECCH.

**Previous Presentation:** This study was presented in part at the Eighth International Symposium on Facial Plastic Surgery; May 5, 2002; New York, NY.

## REFERENCES

1. Koster PH, Bossuyt PM, van der Horst CM, et al. Assessment of clinical outcome after flashlamp pumped pulsed dye laser treatment of portwine stains: a comprehensive questionnaire. *Plast Reconstr Surg*. 1998;102:42-48.
2. Currie CL, Monk BE. Can the response of port-wine stains to laser treatment be reliably assessed using subjective methods? *Br J Dermatol*. 2000;143:360-364.
3. Rah DK, Kim SC, Lee KH, et al. Objective evaluation of treatment effects on port-wine stains using L\*a\*b\* color coordinates. *Plast Reconstr Surg*. 2001;108:842-847.
4. Berinstein TH, Bane SM, Cupp CL, et al. Steroid use in rhinoplasty: an objective assessment of postoperative edema. *Ear Nose Throat J*. 1998;77:40-43.
5. van der Horst CM, Koster PH, de Borgie CA, et al. Effect of the timing of treatment of port-wine stains with the flash-lamp-pumped pulsed-dye laser. *N Engl J Med*. 1998;338:1028-1033.
6. *Arnica montana*. Available at: [http://www.yestheyrefake.net/arnica\\_montana.htm](http://www.yestheyrefake.net/arnica_montana.htm). Accessed January 21, 2002.
7. Homeopathic self sufficiency with *Arnica montana*. Available at: <http://www.geocities.com/HotSprings/7776/ARNICA.HTM>. Accessed January 21, 2002.
8. Alpine Pharmaceuticals: SinEch information. Available at: <http://www.alpinepharm.com>. Accessed May 29, 2002.
9. What is homeopathy? Available at: <http://www.mindspring.com/~jslowe/What%20is.htm>. Accessed January 21, 2002.
10. Homeopathic self sufficiency: about homeopathy. Available at: <http://www.geocities.com/HotSprings/7776/ABOUT-HO.HTM>. Accessed January 21, 2002.
11. Poisonous plants of North Carolina: *Arnica montana*. Available at: <http://www.ces.ncsu.edu/depts/hort/consumer/poison/Arnica.htm>. Accessed January 21, 2002.
12. Kaziro GS. Metronidazole (Flagyl) and *Arnica montana* in the prevention of post-surgical complications: a comparative placebo controlled clinical trial. *Br J Oral Maxillofac Surg*. 1984;22:42-49.
13. Taylor MA, Reilly D, Llewellyn-Jones RH, et al. Randomized controlled trial of homeopathy versus placebo in perennial allergic rhinitis with overview of four trial series. *BMJ*. 2000;321:471-476.
14. Vickers AJ, Fisher P, Smith C, et al. Homeopathic arnica 30x is ineffective for muscle soreness after long-distance running: a randomized, double-blind, placebo-controlled trial. *Clin J Pain*. 1998;14:227-231.
15. Jacobs J, Springer DA, Crothers D. Homeopathic treatment of acute otitis media in children: a preliminary randomized placebo-controlled trial. *Pediatr Infect Dis J*. 2001;20:177-183.
16. Hart O, Mullee MA, Lewith G, et al. Double-blind, placebo-controlled, randomized clinical trial of homeopathic arnica C30 for pain and infection after total abdominal hysterectomy. *J R Soc Med*. 1997;90:73-78.
17. Ferley JP, Zmirou D, D'Adhemar D, Balducci F. A controlled evaluation of a homeopathic preparation in the treatment of influenza-like syndromes. *Br J Clin Pharmacol*. 1989;27:329-335.
18. Poitevin B, Davenas E, Benveniste J. In vitro immunological degranulation of human basophils is modulated by lung histamine and *Apis mellifica*. *Br J Clin Pharmacol*. 1988;25:439-444.
19. Cazin JC, Cazin M, Gaborit JL, et al. A study of the effect of decimal and centesimal dilutions of arsenic on the retention and mobilization of arsenic in the rat. *Hum Toxicol*. 1987;6:315-320.
20. Lo SY, Lo A, Chong LW, Tianzhang L, Hua LH, Geng X. Physical properties of water with I<sub>2</sub> structures. *Mod Phys Lett B*. 1996;10:921-930.
21. Belon P, Cumps J, Ennis M, et al. Inhibition of human basophil degranulation by successive histamine dilutions: results of a European multi-centre trial. *Inflamm Res*. 1999;48(suppl 1):S17-S18.
22. Linde K, Clausius N, Ramirez G, et al. Are the clinical effects of homeopathy placebo effects? a meta-analysis of placebo controlled trials. *Lancet*. 1997;350:834-843.
23. Beyond CMYK: hi-fi colour. Available at: [http://www.designer-info.com/DTP/beyond\\_cmyk.htm](http://www.designer-info.com/DTP/beyond_cmyk.htm). Accessed May 29, 2002.